Temas em Saúde

Artigo de Revisão
ISSN: 2447-2131

ANATOMICAL STUDY OF MESENTERIC VEINS AND THEIR VARIATIONS: A SYSTEMATIC REVIEW AND META-ANALYSIS

https://doi.org/10.64671/ts.v25i1.113

Manoel Pedro de Farias Candido Neto[1*], Philippe Oliveira Lima[1], José Emerson Xavier[1], Valdilene Canazart dos Santos[1], Rafael Danyllo da Silva Miguel[1]

1. Universidade Federal de Alagoas/Campus Arapiraca, Arapiraca, AL

Recebido: setembro 22, 2025 | **Aceite:** novembro 22, 2025 | **Publicação**: dezembro 9, 2025

ABSTRACT

Anatomical variations (AV) are modifications in morphological features that do not imply functional impairment. Among the structures most affected by them are the blood vessels, of which the superior (SMV) and inferior (IMV) mesenteric veins stand out. In this study, we aimed to identify the prevalence of different AVs of SMV and IMV using a systematic review with meta-analysis. The steps taken followed the PRISMA guidelines, and the study protocol was registered and published on the PROSPERO platform (CRD42022336763). R-Studio was used for meta-analysis adopting the random distribution model. The chi-square test and the I-square test were used to investigate heterogeneity and its amplitude, respectively. After all the steps described in the protocol, ten articles were obtained for systematic review and three for meta-analysis. The IMV was a tributary of the splenic vein (SV) in 52% of the cases and the SV, the latter being anastomosing with the SMV to form the hepatic portal vein (HPV) (95% CI 0.38 – 067; $X_2^2 = 5.50$, p= 0.06; I^2=64%). In addition to this pattern, IMV was observed as a tributary of the SMV in 30% of the individuals (95% CI 0.22–0.40; X_2^2= 3.02, p = 0.22; I^2= 34%), and it may also be targeting a common confluence point along with the SMV, SV and the jejunal vein. Thus, this study identified the main destinations of mesenteric vessels, recognizing the prevalence of each of the different conformations that they presented.

Keywords: Anatomy; Mesenteric Veins; Meta-analysis.

1 INTRODUCTION

Anatomical variations are morphological findings in any structure of the human body that differ from their usual description in the literature, that is, they present, size, shape, trajectory, quantity, spatial arrangement, and distribution different from what is described in most of the population (Alraddadi, 2021). However, its existence does not represent functional damage to the organ or system

***Autor Correspondente:** manoel.neto@arapiraca.ufal.br

to which the structure belongs, thus differentiating it from the so-called anomalies (Kachlik et al., 2020).

In blood vessels, anatomical variations are mainly represented by the level of vertebral origin; trunk or branches/tributaries origin/confluence; branches/tributaries distribution; additional branches/tributaries/anastomosis, and morphometric features (diameter and length). However, the maintenance of the individual's state of physiological normality does not exempt anatomical variations from having great relevance for the surgical clinic, either for the optimization of the identification of vessels in patients or for the elaboration of important clinical correlations in pathological conditions that involve irrigation, arterial or venous drainage (Prado Neto and Petroianu, 2022). In this sense, epidemiological studies and case reports are carried out, through cadaveric dissections, imaging tests, and intraoperative analysis, aiming to identify these variations and their respective evaluations related to their frequency in each population (Kornafel et al., 2010).

The hepatic portal vein (HPV) is among the veins with the greatest clinical and surgical relevance, given the significantly high number of liver transplants performed in the world per year, especially in the United States, China, and Brazil (Trotter and Cárdenas, 2016). Due to its importance, Prado Neto and Petroianu (2022) used a systematic review of the literature to describe the conformation patterns of this vessel. The tributaries of the HPV, which include the splenic vein (LV) and the mesenteric veins, also have categorical value in the morphological study (Carneiro et al., 2019), but have not yet been targets of reviews with meta-analysis that could statistically present their different patterns of distribution.

Given the ease of movement of people from one region of the globe to another, morphological characteristics that were previously frequent in a given population may be changing their prevalence (Ogeng', 2013). Thus, this study aimed to analyze which are the main anatomical variations existing in the mesenteric veins and to statistically analyze the prevalence of the different anatomical variations observed, using as a basis for statistical analysis only epidemiological studies carried out with human beings, based on dissection or image exams.

2 METHODOLOGY

This study followed the guidelines of the 2020 statement by PRISMA (*Preferred Reporting Items for Systematic Reviews and Meta-Analysis*) to guide systematic review and meta-analysis reports

CC BY

since it is a method recognized in the literature (Belle and Zhao, 2023). All processes related to search, selection, and eligibility were carried out by two researchers independently (P.O.L. and M.P.F.C.N.). The protocol followed in all stages of this study was registered in PROSPERO (CRD42022336763) and is available online.

Search Strategies and sources

The researchers searched the following online databases: Virtual Health Library (VHL), PubMed, and Scopus for articles that included relevant information on the normal anatomy of the mesenteric veins (SMV and IMV) and their respective anatomical variations. In addition, data regarding the morphometry of these vessels were also collected for this study. There were no restrictions regarding language or date of publication. Searches in virtual libraries were carried out between October 25 and November 3, 2022, using the following DeCS/MeSH descriptors: "Mesenteric Vein"; "Mesenteric Veins"; "Anatomy"; "Anatomical"; "Morphology" and "Morphological". These descriptors were also used in Spanish and Portuguese. The Boolean operator used was AND, combining the descriptors in different ways, as shown in Table 1. The filters used in each of the databases are described in Table 2. After the search, the elimination step was performed for duplicated articles. This stage took place between November 7th and 11th, 2022.

Table 1. Keyword Combinations used in research

NO.	Keyword Combination
1	Mesenteric Vein AND Anatomy
2	Mesenteric Veins AND Anatomy
3	Mesenteric Vein AND Anatomical
4	Mesenteric Veins AND Anatomical
5	Mesenteric Vein AND Morphology
6	Mesenteric Veins AND Morphology
7	Mesenteric Vein AND Morphological
8	Mesenteric Veins AND Morphological

Source: Created by the authors themselves.

Table 2. Research Strategies

DATABASE	CONTENT SEARCHED	FILTERS APPLIED
PUBMED	Title and Abstract	Case Reports; Classical Article; Humans; Adult: 19+ years.
VHL	Title, Abstract and Keywords	Full Text; **Database:** MEDLINE, LILACS, IBECS, BINACIS; **Study Type:** Case Report; Incidence Study; Observational Study; Prevalence Study; Etiology Study; Practice Guideline; Screening Study; Qualitative Research.
SCOPUS	Title and Abstract	Open Access (All Open Access); Document type (Article); Publication stage (Final); Keywords (Human, humans); Source Type (Journal).

Source: Created by the authors themselves.

Inclusion and Exclusion criteria

The evaluation of the inclusion/exclusion criteria took place at two different times, each with different objectives: (1) Critical reading of the Title and Abstract (carried out between November 18th and December 26th, 2022) and (2) Critical reading of the complete article (held between January 13 and February 12, 2023).

Only original articles were included, that used cadavers, imaging exams, and/or during surgical procedures, regardless of whether they were prospective or retrospective studies. Articles that used: a) animal models; b) individuals under 18 years of age; c) individuals with a previous history of abdominal surgeries; d) individuals with pathological conditions that could alter the anatomical

CC BY

characteristics of the intestinal vasculature, such as abdominal trauma, cancer, anomalies, etc. Studies that did not perform any morphological and/or morphometric description of the mesenteric veins were also excluded.

Data extraction and synthesis

From the studies included in this review, the following information was extracted: type of study; study design; publication data, country where it was carried out, objectives, characteristics of the sample (quantity; sex; age; ethnicity; health history; morphological conditions) and methodological information.

Data were grouped as follows: 1- Qualitative analysis: descriptions of the anatomical variations observed in the included studies, regardless of whether it was a case report or an epidemiological study; 2- Quantitative analysis: performed through statistical tests (meta-analysis) using epidemiological studies. For this last analysis, the prevalence of each type of mesenteric vein distribution was observed, and then the total prevalence was calculated, considering all participants involved in the included studies.

Evaluation of the selected studies (AQUA Tool)

To assess the risk of bias, the Anatomical Quality Assessment tool (AQUA tool) was used as an analysis tool, which assigns the classifications: Low, High, and Unclear risk of bias for each of the studies that were included in the meta-analysis. This tool categorizes the risks of bias into five distinct domains, which are: Domain 1: Characterization of the Purpose and Subject Addressed; Domain 2: Study Design; Domain 3: Characterization of the Methodology Used; Domain 4: Description of Anatomy; Domain 5: Presentation of Results.

Each of these domains contains three to five assessment criteria, which consist of yes or no questions. Each evaluator attributed: YES when the evaluated study corresponded to what was required in the criterion; NO when it did not match; UNCLEAR when the study did not make it clear whether it corresponded or not; and NOT APPLICABLE when the study did not fit the question asked.

After the qualitative evaluation of these criteria, the amount of YES, NO, and UNCLEAR was analyzed for each of the domains, individually, for their classification. Those criteria with NOT APPLICABLE were not considered in the total domain evaluation (Table 3). This Bias assessment

CC BY

tool (Henry *et al.*, 2017) is used in systematic reviews of the literature that address the field of morphology (de Oliveira-Neto *et al.*, 2023).

Table 3. Risk of Bias Assessment Guideline

Domain Setting	YES	NO	UNCLEAR	Risk of Bias
5 Criteria	5	0	0	Low
	4	1	0	Low
	4	0	1	Low
	3	2	0	High
	3	0	2	Unclear
	3	1	1	Unclear
	2	3	0	High
	2	0	3	Unclear
	2	2	1	High
	2	1	2	Unclear
	1	2	2	High
	1	1	3	Unclear
	1	3	1	High
	1	4	0	High
	1	0	4	Unclear
	0	0	5	Unclear

CC BY

	0	5	0	High
	0	4	1	High
	0	1	4	Unclear
	0	2	3	High
	0	3	2	High
4 Criteria	4	0	0	Low
	3	1	0	Low
	3	0	1	Low
	2	1	1	Unclear
	2	2	0	High
	2	0	2	Unclear
	1	3	0	High
	1	0	3	Unclear
	1	1	2	Unclear
	1	2	1	High
	0	4	0	High
	0	0	4	Unclear
	0	3	1	High
	0	1	3	Unclear

CC BY

	0	2	2	High
	3	0	0	Low
	2	1	0	High
	2	0	1	Unclear
	1	1	1	High
	1	2	0	High
3 Criteria	1	0	2	Unclear
	0	0	3	Unclear
	0	3	0	High
	0	2	1	High
	0	1	2	High

Source: Created by the authors themselves.

Statistical Analysis

The data collected from the articles included in the qualitative and quantitative analysis were tabulated in a digital spreadsheet. To carry out the meta-analysis, the spreadsheet prepared one of these events as a distinct anatomical variation (Pereira and Galvão, 2014b).

The R-Studio software was used to perform the meta-analysis, adopting the random distribution method. For the analysis of the significance of heterogeneity, the chi-square test was used, considering the p-value more conservative than usual, $p<0.10$. The amplitude of heterogeneity was observed using the I-square test. For this test, values greater than 50% were classified as substantial heterogeneity, and values greater than 75% were classified as considerable heterogeneity (Pereira and Galvão, 2014a).

3 RESULTS AND DISCUSSION

1030 articles were found during the search and selection stage. After excluding duplicates, 388 articles remained. During the screening, 336 articles were removed, leaving 52 for the eligibility stage. The reasons for exclusions in each of the stages are summarized in Figure 1. In the eligibility stage, 42 articles were excluded, leaving 10 for the systematic review and 3 for the meta-analysis. Of the ten articles included in the qualitative synthesis of the data, it was observed that six were case reports (4 studies with cadavers and 2 with patients (Gorantla, B. K. Potu, *et al.*, 2007; Falkowski *et al.*, 2014a; Fakoya *et al.*, 2020a; Coskun *et al.*, 2021a; Şelaru *et al.*, 2021a; Ziegler, Schwarz and Tschernig, 2021a) and four epidemiological studies (2 studies with cadavers and 2 with living patients)(Ibukuro *et al.*, 1996a; I. B. Cabrera *et al.*, 2005; Kadel and Pandit, 2020a; Russkikh, 2022a) The data extracted from each article are summarized in Table 4.

Figure 1. PRISMA Flowchart

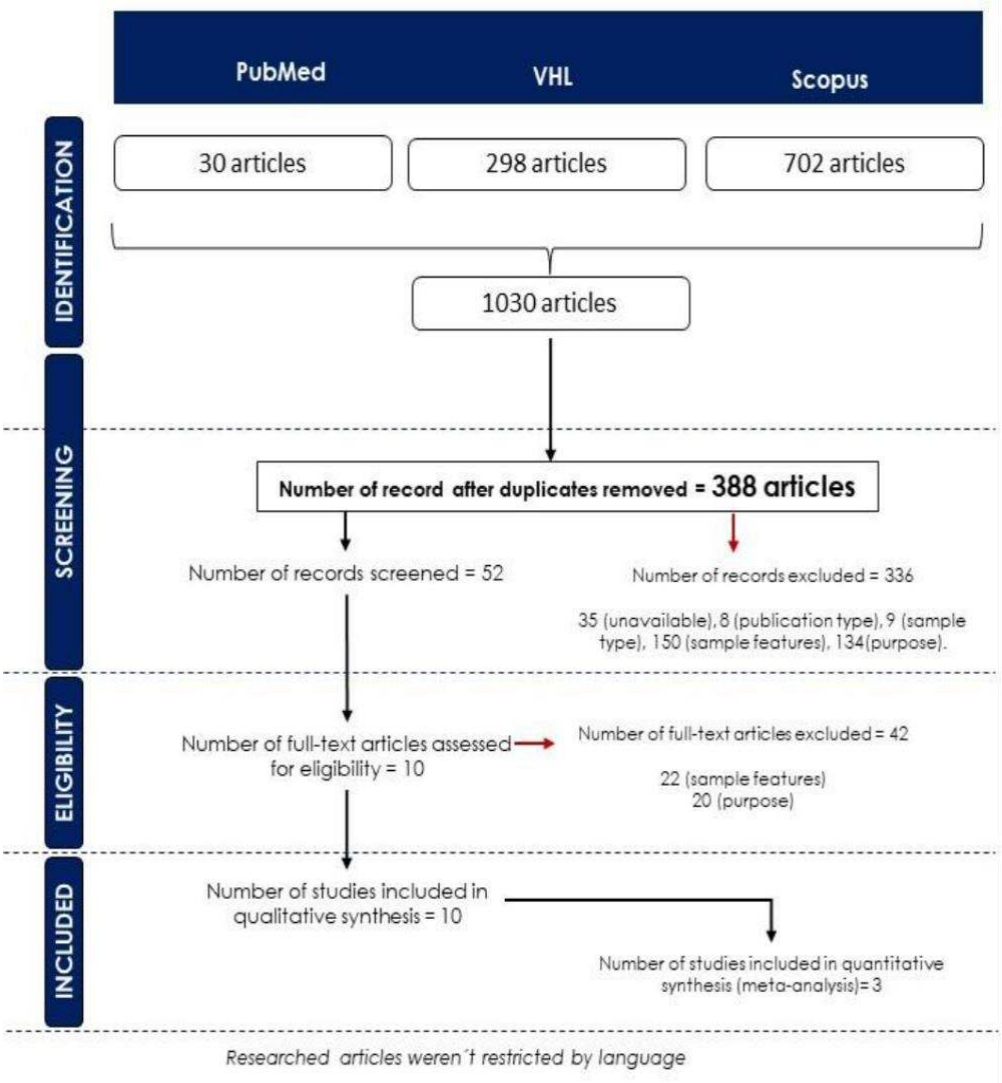

Source: Created by the authors themselves.

CC BY

Table 04: Synthesis of Extracted Data

QUOTE	STUDY AIM	STUDY TYPE	VARIATION TYPE	RESULTS	ADDITIONAL INFO
(GORANTLA et al., 2007)	Describe a type of anatomical variation in the formation of the hepatic portal vein.	Case Report.	Mesenteric vessels destinations	The SMV and IMV of the analyzed cadaver joined with the SV, forming the VPH.	Study Population: 54-year-old male corpse
(ŞELARU et al., 2021)	Describe anatomical variations of abdominal vessels in a patient.	Case Report.	Morphometrical analysis of the mesenteric veins	The SMV had a diameter of 8.921 mm and the IMV 9.204 mm.	Study Population: 62-year-old woman Imaging Technique: Computed tomography
(RUSSKIKH, 2022)	Morphometrically analyze the elements that make up the hepatic portal system.	Epidemiological Study	Morphological and morphometric analysis of mesenteric veins.	The SMV had an average length of 93.5 mm and a diameter of 9.5 mm. Its tributaries were: middle colic vein, jejunal vein, suprailiac vein, jejunal suprailiac vein, right colic vein and right gastroepiploic vein. Regarding the IMV, it was on average 108.5 mm long and 4.5 mm in diameter. Its tributaries were: left colic vein, superior rectal vein and sigmoid colon vein.	Study Population: 53 male individuals Age Range: 36 to 71 years Mean Age: 54.9 ± 1.7 years Imaging Technique: Computed tomography.
(ZIEGLER; SCHWARZ; TSCHERNIG, 2021)	Describe a case of hepatic portal vein variation	Case Report.	Fate of mesenteric vessels.	The cadaver presented two HPV, where the left HPV was formed by the SV and IMV, and the right HPV was the continuation of the SMV.	Study Population: 84-year-old male corpse Cause of Death: Sepsis and respiratory failure

CC BY

(FAKOYA et al., 2020)	Describe a case of anatomical variation of the tributaries of the inferior mesenteric vein	Case Report.	Anatomical variation of tributaries.	The IMV did not present the sigmoid colon vein as one of its tributaries.	Study Population: 80-year-old Caucasian male cadaver
(IBUKURO et al., 1996)	Describe the morphometry and anatomical variations of the mesenteric veins	Epidemiological Study	Morphological and morphometric analysis of mesenteric vessels.	Middle colic vein drains into SMV at an average of 2.4 cm ± 1.1 cm below the confluence of the SV with the HPV; the gastro-colic trunk drains into the SMV 3.0 ± 0.6 cm below the confluence of the SV with the HPV; the first jejunal vein drains into the SMV 3.7 ± 0.9 cm below the confluence of the SV with the HPV; the IMV anastomoses with the SV in 43.18% of cases; IMV together with SV and SMV unite in 25% of cases to form HPV; and in 29.54% of cases the IMV drains into the SMV. The first jejunal vein was anterior to the SMV in 10.42% of cases and posterior in 89.58%. The middle colic vein drained into the proximal portion of the SMV in 75% of cases, into the IMV in 11.11% and into the gastrocolic trunk in 13.9%.	Study Population: 50 patients (22 females and 28 males) Age Range: 23 to 79 years Mean Age: 55 years Imaging Technique: Computed tomography
(FALKOWSKI et al., 2014)	Report the case of an anatomical variation in the mesenteric veins	Case Report.	Fate of mesenteric vessels.	IMV presented itself as being a tax agent of SMV.	Patient Description: 60-year-old Female Imaging Technique: Computed tomography examination

CC BY

(CABRERA et al., 2005)	Describe the morphology of mesenteric vessels in the formation of the hepatic portal vein.	Epidemiological Study	Morphology of the fate of mesenteric veins	In 75% of cadavers, HPV was formed by the union between SMV and SV, with IMV being a tributary of SV. In 15% of the cadavers, the IMV was a tributary of the SMV. Finally, in 10% of cases, HPV was formed by the anastomosis between the SMV, IMV and SV.	Study Population: 20 cadavers Preservation Period: 6 to 12 months
(COSKUN et al., 2021)et al., 2021	Report a case of anatomical variation of mesenteric vessels	Case Report.	Morphology of the fate of mesenteric vessels	IMV presented itself as one of SMV's tributaries.	Study Population: 66-year-old male corpse
(KADEL; PANDIT, 2020)	Describe the morphology of the vessels that form the hepatic portal vein	Epidemiological Study	Morphology of the fate of mesenteric vessels.	In 45% of the cadavers, IMV was a tributary of SV; As a result, HPV was formed by the union between SMV and SV. In 37.5%, IMV was taxed by SMV. In 12.5% of cases, IMV and SMV join with SV to form HPV. Finally, in 5% of cadavers, the SMV, IMV and SV unite with the jejunal vein to form HPV .	Study Population: 40 cadavers (37 male and 3 female).

Risk of Bias evaluation

Of the studies included in the meta-analysis, only one had a high risk of bias for the first domain. For the second and fourth domains, the three included articles had a low risk of bias. As for the third domain, one article had a high risk of bias, another had a low risk, and the third had an undetermined risk. Finally, in the fifth domain, all articles showed a high risk of bias. Table 5 represents the risk of bias analysis for each domain criterion.

Table 5. Risk of Bias Assessment for articles included in the Meta-analysis

AUTHOR	Study design	Domain 1			Domain 2				Domain 3					Domain 4				Domain 5				SCORE
		1	2	3	4	5	6	7	8	9	10	11	12	13	14	15	16	17	18	19	20	
(CABRERA et al., 2005)	Descriptive/ Cadaveric study	Y	Y	N	Y	Y	Y	Y	Y	N	N	U	N	Y	Y	NA	Y	N	Y	Y	N	High Risk
(IBUKURO et al., 1996)	Descriptive study	Y	Y	Y	Y	Y	Y	Y	Y	Y	Y	Y	N	Y	Y	Y	Y	Y	N	Y	N	Low Risk
KADEL; PANDIT, 2020)	Descriptive/ Cadaveric study	Y	Y	Y	Y	Y	Y	Y	Y	N	Y	U	Y	Y	Y	Y	Y	N	Y	Y	N	Low Risk

Source: Created by the authors themselves.

Qualitative Analysis

Main tributaries of the Mesenteric Veins

The mesenteric vessels are mainly formed from the anastomoses of the veins that drain the gastrointestinal tract, originating the SMV and the IMV., right and right gastroenteric colic (Russkikh, 2022a). The middle colic vein reached the SMV below the point of confluence between the SV and

CC BY

the HPV, at an average distance of 2.4 cm. Also considering this point of confluence between the SV and the HPV, it was observed that the right gastromental vein and the first jejunal vein drained to the SMV, distant from this point, on average, 3.0 cm and 3.7 cm, respectively (Ibukuro *et al.*, 1996a).

The left colic and superior rectal veins and the sigmoid colon vein were tributaries of IMV (Russkikh, 2022a), although in one of the case reports the latter was absent (Fakoya *et al.*, 2020a). articles included in the present review, data referring to the morphometric analysis on the tributaries of the IMV.

Mesenteric veins contribution to form the Portal Hepatic Vein

In general, the IMV is one of the tributaries of the VE, which, in turn, anastomoses with the SMV to form the HPV (Ibukuro *et al.*, 1996a; I. B. Cabrera *et al.*, 2005; Kadel and Pandit, 2020a), as depicted in Figure 2A. The HPV is a single vessel that carries blood drained from most abdominal organs to the liver. It is one of the anatomical references and/or target of surgical procedures in almost all liver transplants performed worldwide (Ramalingam *et al.*, 2023; Toth and Barman, 2023) This vein, in one of the included studies, was duplicated, in a left and a right HPV. While the left HPV was formed by the anastomosis between the SV and the SMV, the right HPV was the cranial continuation of the IMV (Ziegler, Schwarz and Tschernig, 2021a).

In two investigated case reports, it was observed that the IMV was a tributary vessel of the SMV (Falkowski *et al.*, 2014a; Coskun *et al.*, 2021a), as shown in Figure 2B. Epidemiological analysis demonstrated that this conformational pattern was present in the population oscillating between 15% and 37.5% of the cases (Ibukuro *et al.*, 1996a; I. B. Cabrera *et al.*, 2005; Kadel and Pandit, 2020a). In these situations, the HPV was formed from the anastomosis between the SMV and the SV (Ibukuro *et al.*, 1996a; I. B. Cabrera *et al.*, 2005; Falkowski *et al.*, 2014a; Kadel and Pandit, 2020a; Coskun *et al.*, 2021a)

Another anatomical variation found was the confluence of the SV, IMV, and SMV to form the HPV (Gorantla, B. K. Potu, *et al.*, 2007). This variation was present in between 10% and 25% of the cases (Ibukuro *et al.*, 1996a; I. B. Cabrera *et al.*, 2005; Kadel and Pandit, 2020a) and is represented in Figure 2C. An additional vein, the jejunal vein, could converge together with the IMV, SMV, and SV in the formation of the HPV (Figure 2D), with this arrangement being present in 5% of the cases (Kadel and Pandit, 2020a).

Figure 2. Schematic representation of the main observed variations of the mesenteric veins in the formation of HPV.

CC BY

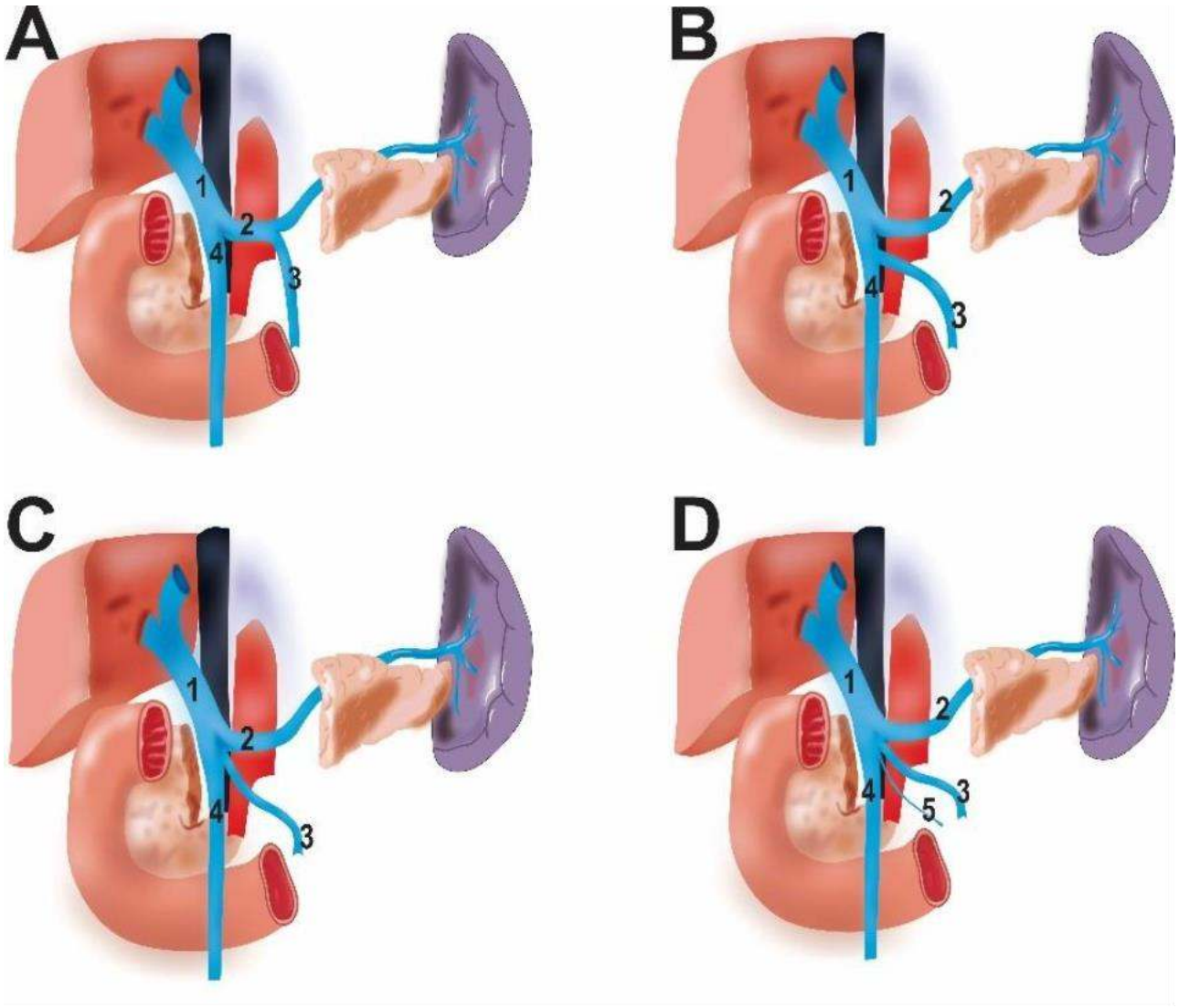

Source: Created by the authors themselves.

Quantitative Analysis: Metanalysis

Through meta-analysis, it was observed that the most common conformation of anastomoses, with 0.52 (95% CI 0.38 – 067; $X_2^2 = 5.50$, p= 0.06; I^2 =64%) for formation of the hepatic portal vein, was the one in that the IMV anastomoses with the VE and this, in turn, with the SMV, thus forming the HPV(Ibukuro *et al.*, 1996a; I. B. Cabrera *et al.*, 2005; Kadel and Pandit, 2020a) (Figure 3).

Figure 3. Results obtained through meta-analysis of the included articles

CC BY

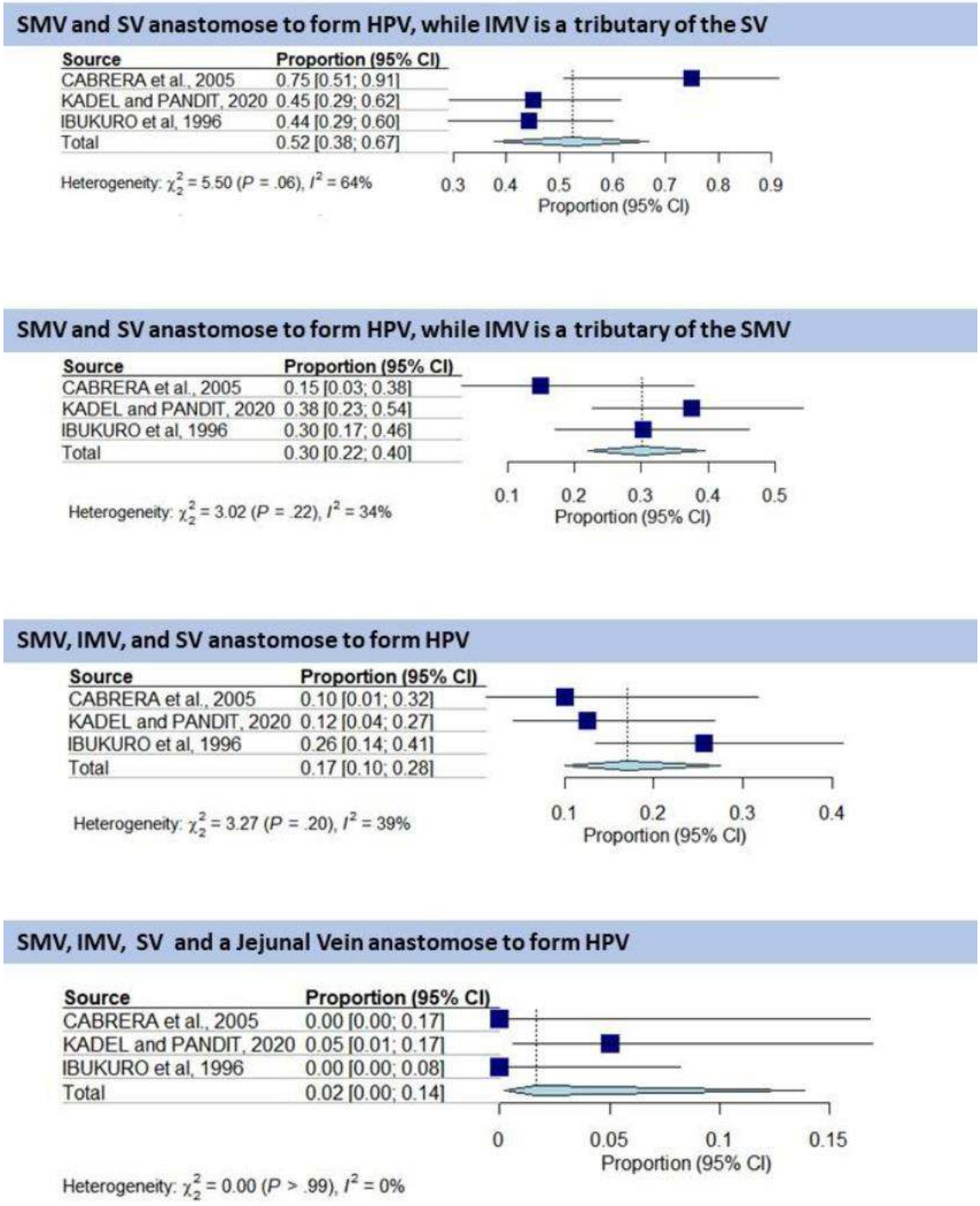

Source: Created by the authors themselves.

From the aforementioned distribution, the most prevalent anatomical variation was that of the IMV being a tributary of the SMV, 0.30 (95% CI 0.22–0.40; X_2^2 = 3.02, p=0.22; I^2=34%), followed by the variation in which there was an anastomosis between the SMV, IMV, and SV to form the HPV, obtaining a prevalence of 0.17 (95% CI 0.10 – 0.28; X_2^2 = 3.27 p=0.20; I^2=39%). Finally, the least frequent variation was the one in which, in addition to the anastomosis between the SMV, IMV, and

CC BY

SV, there was also the confluence of the jejunal vein. This last configuration presented a prevalence of 0.02 (95% CI 0.00 – 0.14; $X_2^2 = 0.00$, p>0.99; I^2=0%) (Ibukuro *et al.*, 1996a; I. B. Cabrera *et al.*, 2005; Kadel and Pandit, 2020a) (Figure 3).

Recognition of the anatomy of the mesenteric veins is important when looking at the consequences of changes in their normal blood flow. These changes can lead to increased venous pressure, increased hydrostatic pressure, and edema of the intestinal wall, triggering severe symptoms for the patient (Treffalls *et al.*, 2023). compression by the uterus during pregnancy (Oldenkamp and Kitamura, 2023), which constitutes a non-obstetric surgical emergency. In addition, mesenteric vein thrombosis has been identified as a possible complication of polycystic ovary syndrome (Abuhammad *et al.*, 2023) and also part of the vast symptomatology of infection by the Sars-Cov-2 virus (Zhu *et al.*, 2020; Amaravathi *et al.*, 2021; Messina *et al.*, 2022). In the situations presented, the risks of portal occlusion could be assumed from an analysis of the types of variation of the confluence of the mesenteric and splenic veins presented in this study, since the greater the number of confluences before the formation of HPV, the lower the risk (Cao *et al.*, 2023). Thus, the type of conformation represented in Figure 2B would be the least susceptible in cases of thrombosis in IMV, while the one represented in Figure 2D would be the most susceptible among them.

4 CONCLUSION

In this study, the main anatomical variations of the mesenteric veins already reported in the literature and their prevalence were presented. It was possible to verify that the IMV is a tributary of the SV in more than half of the individuals analyzed in the primary studies included in this meta-analysis, with the SV anastomosing with the SMV to form the HPV. Although this was the most frequent conformation, approximately one-third of the individuals had the IMV as a tributary of the SMV, while approximately one-fifth had the anastomosis of the SMV, IMV, and SV to form the HPV. Finally, the rarest anatomical variation found was the anastomosis between the SMV, IMV, SV, and jejunal vein for the formation of the HPV, which was present in two percent of the individuals. In this sense, it is understood that anatomical variations in these vessels are not uncommon, having direct implications in the analysis of imaging exams and in surgical procedures that cover the abdominal region.(Ibukuro et al., 1996b; iris C. Cabrera et al., 2005; Gorantla, K. B. Potu, et al., 2007; Falkowski

CC BY

et al., 2014b; Fakoya et al., 2020b; Kadel and Pandit, 2020b; Coskun et al., 2021b; Şelaru et al., 2021b; Ziegler, Schwarz and Tschernig, 2021b; Russkikh, 2022b).

ACKNOWLEDGEMENTS

The authors would like to thank the support provided by the *Conselho Nacional de Desenvolvimento Científico e Tecnológico* (CNPq) and the *Fundação de Amparo à Pesquisa do Estado de Alagoas* (FAPEAL) for all the support granted for the development of this study.

CONFLICTS OF INTEREST

The authors declare no conflicts of interest.

USE OF ASSISTIVE TECHNOLOGIES AND AI

We declare that no Artificial Intelligence resources were used in the process of preparing this manuscript.

5 REFERENCES

Abuhammad, A. *et al.* (2023) 'Mesenteric and portal vein thrombosis, a rare complication in a patient with polycystic ovary syndrome: A case report and review of literature', *International Journal of Surgery Case Reports*, 109. Available at: https://doi.org/10.1016/j.ijscr.2023.108606.

Alraddadi, A. (2021) 'Literature Review of Anatomical Variations: Clinical Significance, Identification Approach, and Teaching Strategies', *Cureus* [Preprint]. Available at: https://doi.org/10.7759/cureus.14451.

Amaravathi, U. *et al.* (2021) 'Superior Mesenteric Arterial and Venous Thrombosis in COVID-19', *Journal of Emergency Medicine*, 60(5), pp. e103–e107. Available at: https://doi.org/10.1016/j.jemermed.2020.12.016.

Belle, A.B. and Zhao, Y. (2023) 'Evidence-based decision-making: On the use of systematicity cases to check the compliance of reviews with reporting guidelines such as PRISMA 2020', *Expert Systems with Applications*, 217. Available at: https://doi.org/10.1016/j.eswa.2023.119569.

Cabrera, iris C. *et al.* (2005) 'Variantes anatómicas en la irrigación hepática y vías biliares', *Archivo Médico de Camaguey*, 9(5), pp. 36–45. Available at: http://scielo.sld.cu/scielo.php?script=sci_arttext&pid=S1025-02552005000500005 (Accessed: 27 August 2023).

Cabrera, I.B. *et al.* (2005) 'Anatomic variants in liver irrigation and biliary tract', *Archivo Médico de Camagüey* [Preprint].

Cao, H. *et al.* (2023) 'Influence of morphology and hemodynamics on thrombosis in kawasaki disease patients', *Medicine in Novel Technology and Devices*, 18. Available at: https://doi.org/10.1016/j.medntd.2023.100225.

Carneiro, C. *et al.* (2019) 'All about portal vein: a pictorial display to anatomy, variants and physiopathology', *Insights into Imaging*. Springer Verlag. Available at: https://doi.org/10.1186/s13244-019-0716-8.

Coskun, Z.K. *et al.* (2021a) 'Variation of the inferior mesenteric Vein's drainage pattern and its clinical significance', *Gazi Medical Journal*, 32(3), pp. 436–438. Available at: https://doi.org/10.12996/GMJ.2021.98.

Coskun, Z.K. *et al.* (2021b) 'Variation of the inferior mesenteric Vein's drainage pattern and its clinical significance', *Gazi Medical Journal*, 32(3), pp. 436–438. Available at: https://doi.org/10.12996/GMJ.2021.98.

Fakoya, A.O.J. *et al.* (2020a) 'Multiple gastrointestinal vascular variations in a male cadaver: A case report and literature review of embryonic, genetic, and clinicosurgical implications of pathogenicity', *Open Access Macedonian Journal of Medical Sciences*, 8(C), pp. 106–112. Available at: https://doi.org/10.3889/oamjms.2020.4543.

Fakoya, A.O.J. *et al.* (2020b) 'Multiple gastrointestinal vascular variations in a male cadaver: A case report and literature review of embryonic, genetic, and clinicosurgical implications of pathogenicity', *Open Access Macedonian Journal of Medical Sciences*, 8(C), pp. 106–112. Available at: https://doi.org/10.3889/oamjms.2020.4543.

Falkowski, A.L. *et al.* (2014a) 'Pylephlebitis of a variant mesenteric vein complicating sigmoid diverticulitis', *Journal of Radiology Case Reports*, 8(2), pp. 37–45. Available at: https://doi.org/10.3941/jrcr.v8i2.1698.

Falkowski, A.L. *et al.* (2014b) 'Pylephlebitis of a variant mesenteric vein complicating sigmoid diverticulitis', *Journal of Radiology Case Reports*, 8(2), pp. 37–45. Available at: https://doi.org/10.3941/jrcr.v8i2.1698.

Gorantla, V.R., Potu, B.K., *et al.* (2007) 'Anomalous formation of the portal vein: a case report', *Jornal Vascular Brasileiro* [Preprint].

Gorantla, V.R., Potu, K.B., *et al.* (2007) 'Anomalous formation of the portal vein: a case report', *J Vasc Bras*, 6(4), pp. 399–401.

Henry, B.M. *et al.* (2017) 'Development of the anatomical quality assessment (AQUA) tool for the quality assessment of anatomical studies included in meta-analyses and systematic reviews', *Clinical Anatomy*. John Wiley and Sons Inc., pp. 6–13. Available at: https://doi.org/10.1002/ca.22799.

Ibukuro, K. *et al.* (1996a) *Peripancreatic Veins on Thin-Section (3 mm) Helical CT*, *AJR*. Available at: www.ajronline.org.

Ibukuro, K. *et al.* (1996b) 'PeripancreaticVeins on Thin-Section (3 mm) Helical CT', *American Journal of Roentgenology*, 167, pp. 1003–1008. Available at: www.ajronline.org.

CC BY

Kachlik, D. *et al.* (2020) 'Variant anatomy and its terminology', *Medicina (Lithuania)*, 56(12), pp. 1–16. Available at: https://doi.org/10.3390/medicina56120713.

Kadel, M. and Pandit, T.K. (2020a) 'Variations in the Formation of Hepatic Portal Vein: A Cadaveric Study', *Journal of Nepal Health Research Council*, 18(2), pp. 224–227. Available at: https://doi.org/10.33314/jnhrc.v18i2.2421.

Kadel, M. and Pandit, T.K. (2020b) 'Variations in the Formation of Hepatic Portal Vein: A Cadaveric Study', *Journal of Nepal Health Research Council*, 18(2), pp. 224–227. Available at: https://doi.org/10.33314/jnhrc.v18i2.2421.

Kornafel, O. *et al.* (2010) 'Analysis of anatomical variations of the main arteries branching from the abdominal aorta, with 64-detector computed tomography', *Polish Journal of Radiology*, 75, pp. 38–45. Available at: http://www.polradiol.com/fulltxt.php?ICID=878515.

Messina, F. *et al.* (2022) 'A simultaneous superior mesenteric arterial and venous thrombosis in an elderly woman with a previous COVID-19 pneumonia: A suggestive case report diagnosed at computed tomography angiography', *Radiology Case Reports*, 17(8), pp. 2869–2873. Available at: https://doi.org/10.1016/j.radcr.2022.05.027.

Ogeng', J. (2013) *CLINICAL SIGNIFICANCE OF ANATOMICAL VARIATIONS*, *Chief Anatomy Journal of Africa*.

Oldenkamp, C.L. and Kitamura, K. (2023) 'Nonobstetric Surgical Emergencies in Pregnancy', *Emergency Medicine Clinics of North America*. W.B. Saunders, pp. 259–267. Available at: https://doi.org/10.1016/j.emc.2023.01.001.

de Oliveira-Neto, O.B. *et al.* (2023) 'Prevalence of canalis sinuosus and accessory canals of canalis sinuosus on cone beam computed tomography: a systematic review and meta-analysis', *International Journal of Oral and Maxillofacial Surgery*, 52(1), pp. 118–131. Available at: https://doi.org/10.1016/j.ijom.2022.06.011.

Pereira, M.G. and Galvão, T.F. (2014a) 'Heterogeneidade e viés de publicação em revisões sistemáticas', *Epidemiologia e Serviços de Saúde*, 23(4), pp. 775–778. Available at: https://doi.org/10.5123/s1679-49742014000400021.

Pereira, M.G. and Galvão, T.F. (2014b) 'Revisões sistemáticas da literatura: passos para sua elaboração', *Epidemiologia e Serviços de Saúde*, 23(1), pp. 183–184. Available at: https://doi.org/10.5123/s1679-49742014000100018.

Prado Neto, E.V. and Petroianu, A. (2022) 'ANATOMICAL VARIATIONS OF PORTAL VENOUS SYSTEM: IMPORTANCE IN SURGICAL CLINIC', *Arquivos Brasileiros de Cirurgia Digestiva*, 35. Available at: https://doi.org/10.1590/0102-672020210002e1666.

Ramalingam, V. *et al.* (2023) 'Interventional Approach to Portal Vein Thrombosis and Liver Transplantation: State of the Art', *Life*, 13(6), p. 1262. Available at: https://doi.org/10.3390/life13061262.

Russkikh, A.N. (2022a) 'Human portal system morphometry based on 3D computer aided modelling', *European Journal of Anatomy*, 26(2), pp. 159–166. Available at: https://doi.org/10.52083/OUWB2921.

CC BY

Russkikh, A.N. (2022b) 'Human portal system morphometry based on 3D computer aided modelling', *European Journal of Anatomy*, 26(2), pp. 159–166. Available at: https://doi.org/10.52083/OUWB2921.

Şelaru, M. *et al.* (2021a) 'Hepatomesenteric trunk, gastrosplenic trunk, coiled splenic and hepatic arteries, and a variant of Bühler's arc', *Folia Morphologica (Poland)*, 80(4), pp. 1032–1036. Available at: https://doi.org/10.5603/FM.A2020.0136.

Şelaru, M. *et al.* (2021b) 'Hepatomesenteric trunk, gastrosplenic trunk, coiled splenic and hepatic arteries, and a variant of Bühler's arc', *Folia Morphologica (Poland)*, 80(4), pp. 1032–1036. Available at: https://doi.org/10.5603/FM.A2020.0136.

Toth, J.F. and Barman, P. (2023) 'Portal vein thrombosis: Before, during, and after liver transplant', *Clinical Liver Disease*, 22(1), pp. 14–17. Available at: https://doi.org/10.1097/CLD.0000000000000067.

Treffalls, R.N. *et al.* (2023) 'Acute management of mesenteric emergencies: Tailoring the solution to the problem', *Seminars in Vascular Surgery*. W.B. Saunders, pp. 234–249. Available at: https://doi.org/10.1053/j.semvascsurg.2023.04.007.

Trotter, J.F. and Cárdenas, A. (2016) 'Liver transplantation around the world', *Liver Transplantation*. John Wiley and Sons Ltd, pp. 1059–1061. Available at: https://doi.org/10.1002/lt.24508.

Zhu, N. *et al.* (2020) 'A Novel Coronavirus from Patients with Pneumonia in China, 2019', *New England Journal of Medicine*, 382(8), pp. 727–733. Available at: https://doi.org/10.1056/nejmoa2001017.

Ziegler, L., Schwarz, K. and Tschernig, T. (2021a) 'Minireview and case report: Duplication of the portal vein and combinations', *Translational Research in Anatomy*, 25. Available at: https://doi.org/10.1016/j.tria.2021.100154.

Ziegler, L., Schwarz, K. and Tschernig, T. (2021b) 'Minireview and case report: Duplication of the portal vein and combinations', *Translational Research in Anatomy*, 25. Available at: https://doi.org/10.1016/j.tria.2021.100154.

CC BY